



Radiology Techniques

Department

The Radiological Anatomy

Lecture 8

Reproductive tract

By

MS.c Zeyad Tareq & MS.c Salman Mohammed

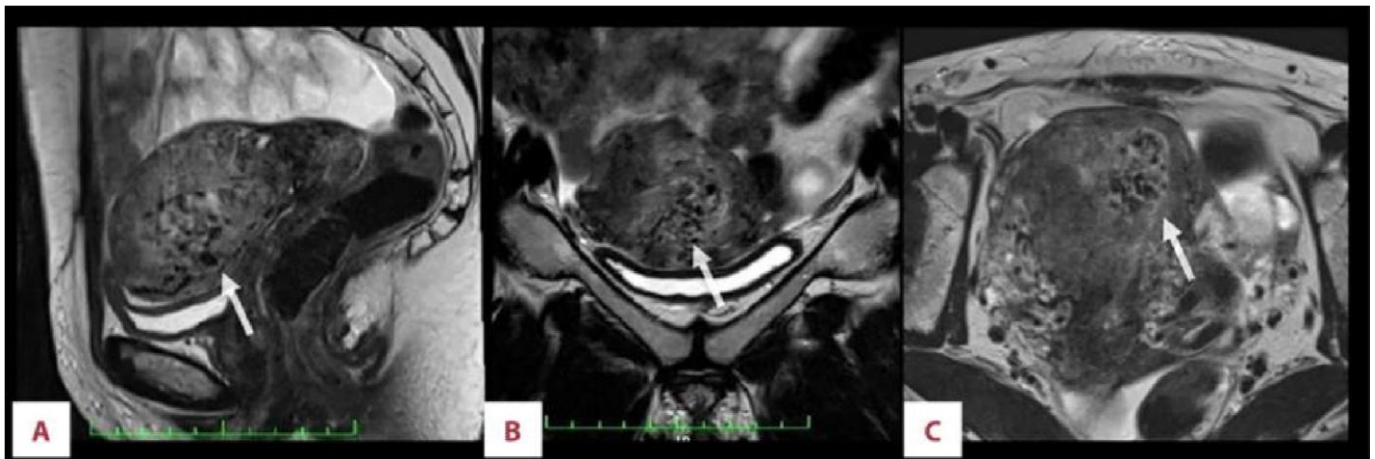
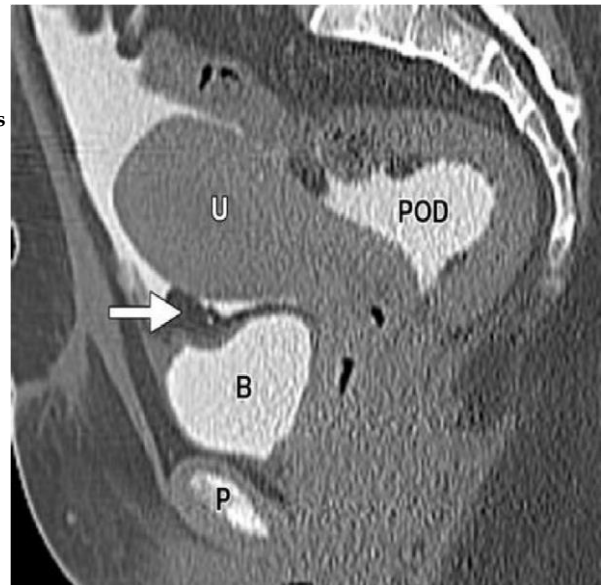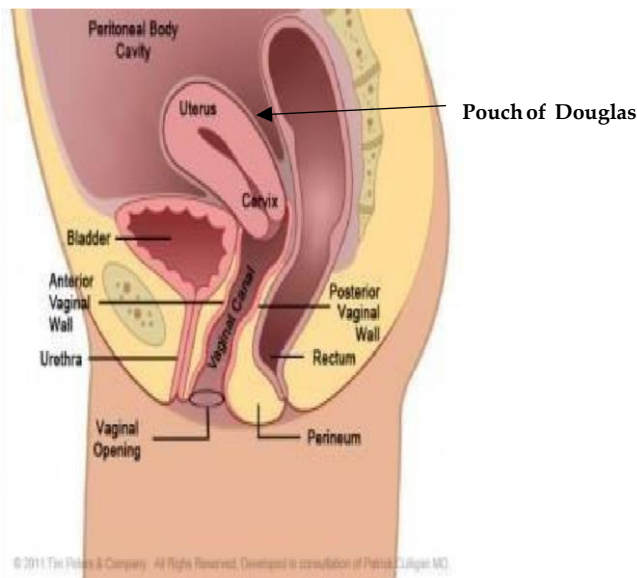
3rd Stage

2022-2023

Female reproductive tract

The vagina:

- ✚ Is an extra-peritoneal structure
- ✚ Superiorly the **cervix** of the uterus
- ✚ The cervix invaginates the upper vagina and divides it into anterior, posterior and lateral **fornixes**
- ✚ Anterior to vagina: **base of bladder** and the urethra.
- ✚ Posterior to upper vagina is the **pouch of Douglas**
- ✚ Posterior and below pouch of Douglas is the **rectum**
- * Pouch of Douglas is a **peritoneal reflection**



Sagittal

coronal

axial

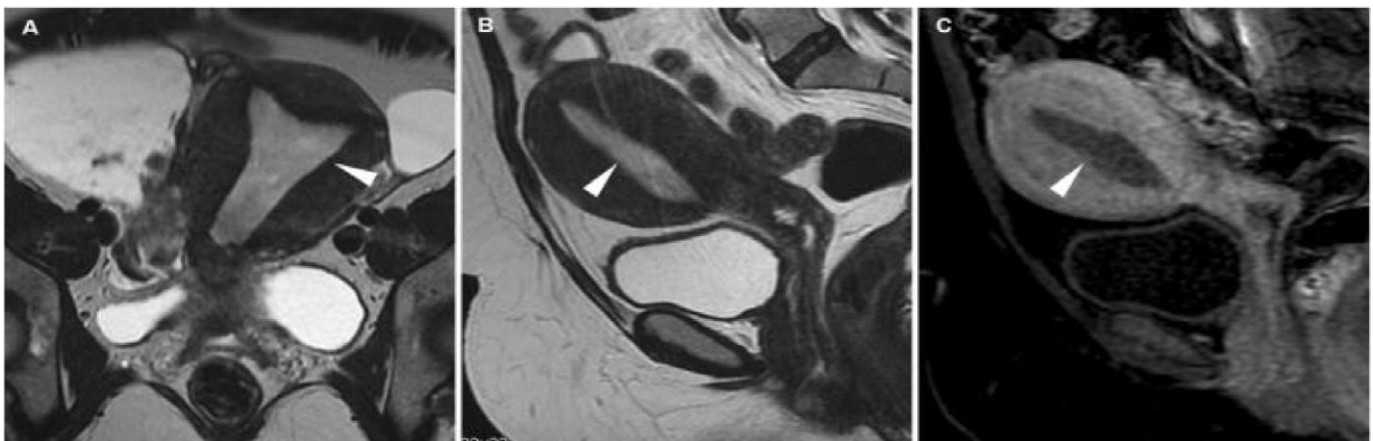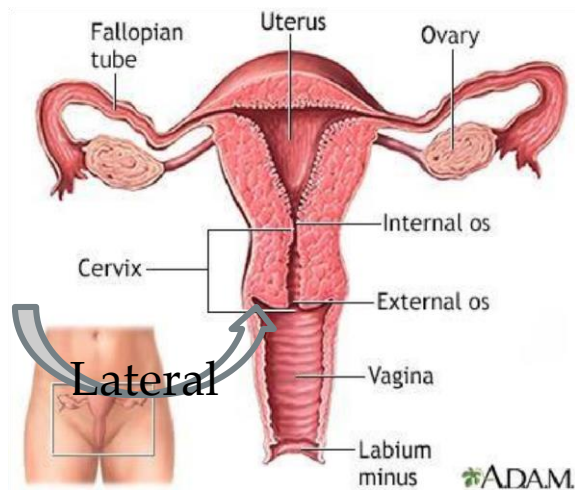
The Uterus:

- ✚ Is **extra peritoneal** ✚ Pear shape organ
- ✚ Lies between the **bladder** and **rectum**
Consists from 3 parts: **1. Fundus** **2. Body** **3. Cervix**
- ✚ The cavity of the uterus is **triangular in coronal section**
- ✚ The cervix contains the **cervical canal** with upper opening called (**internal Os**) and lower opening called (**external Os**)
- ✚ The inner lining of the uterus called the **Endometrium**

The **cervical os** is part of the **cervix**, which is in the lower part of the **uterus**.

It connects the main part of the uterus to the vagina.

Woman's lifetime.



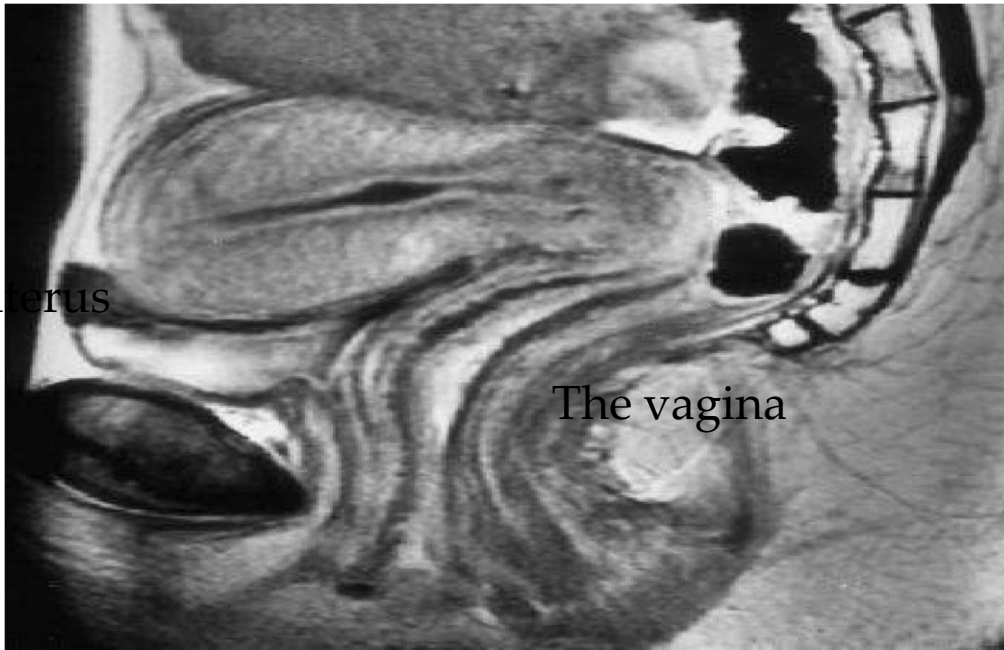T2

T1

FS T1

The cervix is about 2 inches in length but can vary in length and width during a

The uterus

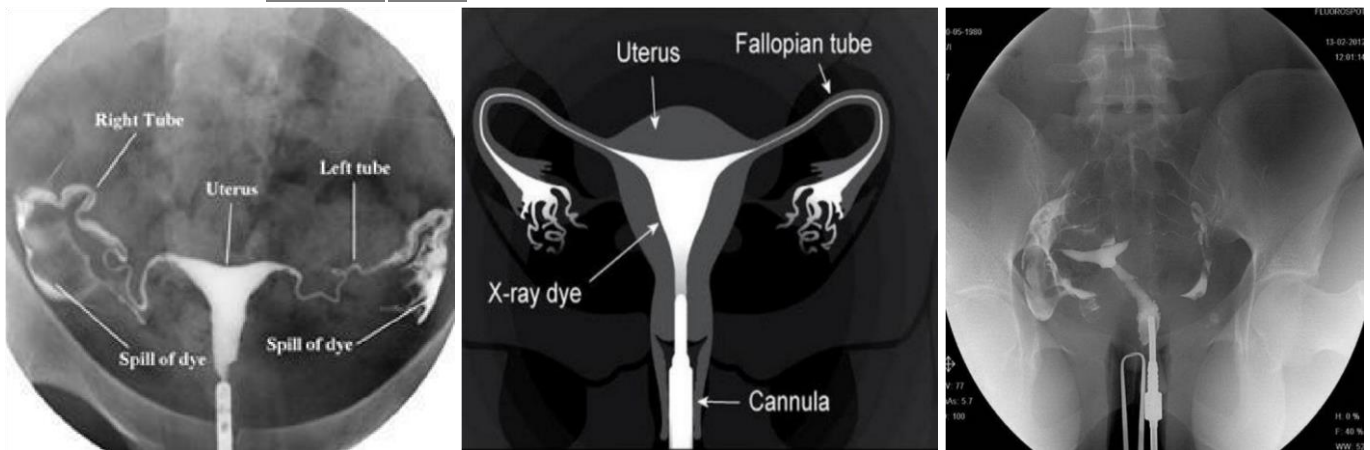


The vagina

Hysterosalpingography

- ✚ The peritoneum covers the fundus, cervix, and upper part of the vagina posteriorly then it is reflected to the anterior surface of the rectum forming the **pouch of Douglas**.
- ✚ On either side of the uterus the peritoneum is reflected to lateral pelvic walls covering the **Fallopian tube**, the fold of peritoneum formed is called the **Broad ligament**.

contrast via the cervical canal

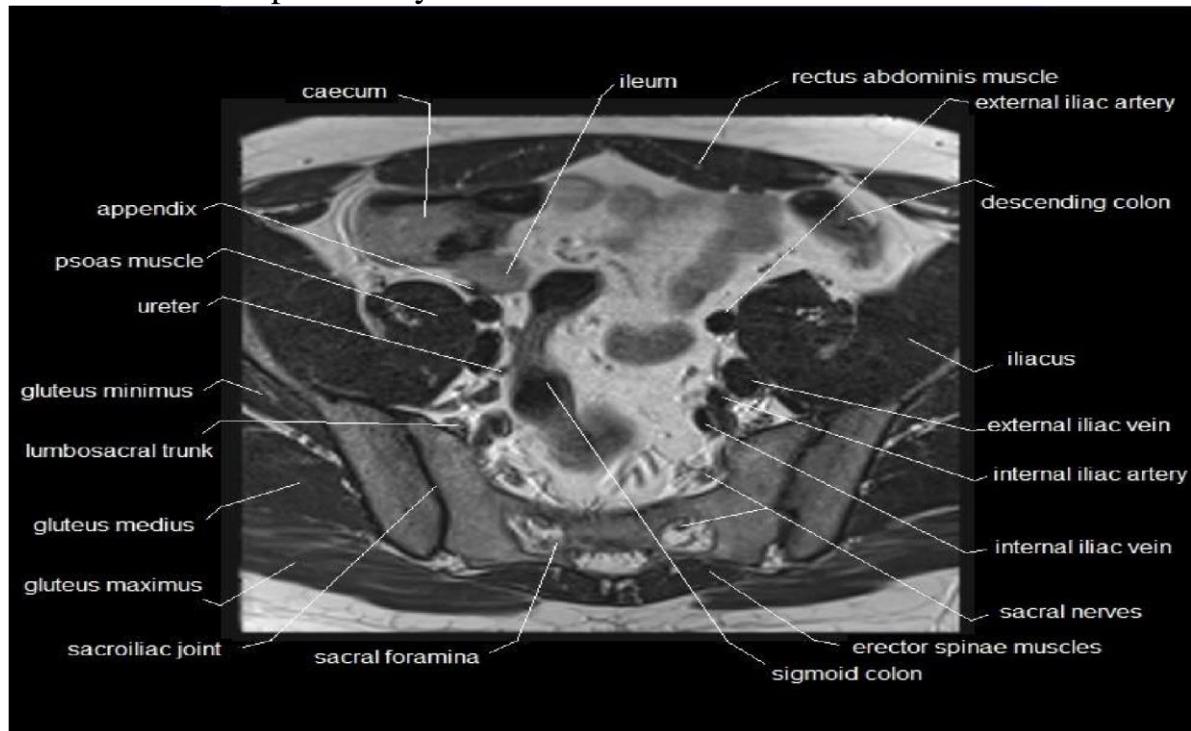


Cross sectional pelvicanatomy:

- ✚ This technique outlines the **cavity of the uterus and tubes** by injecting a water-soluble

Mid sacral level (female).

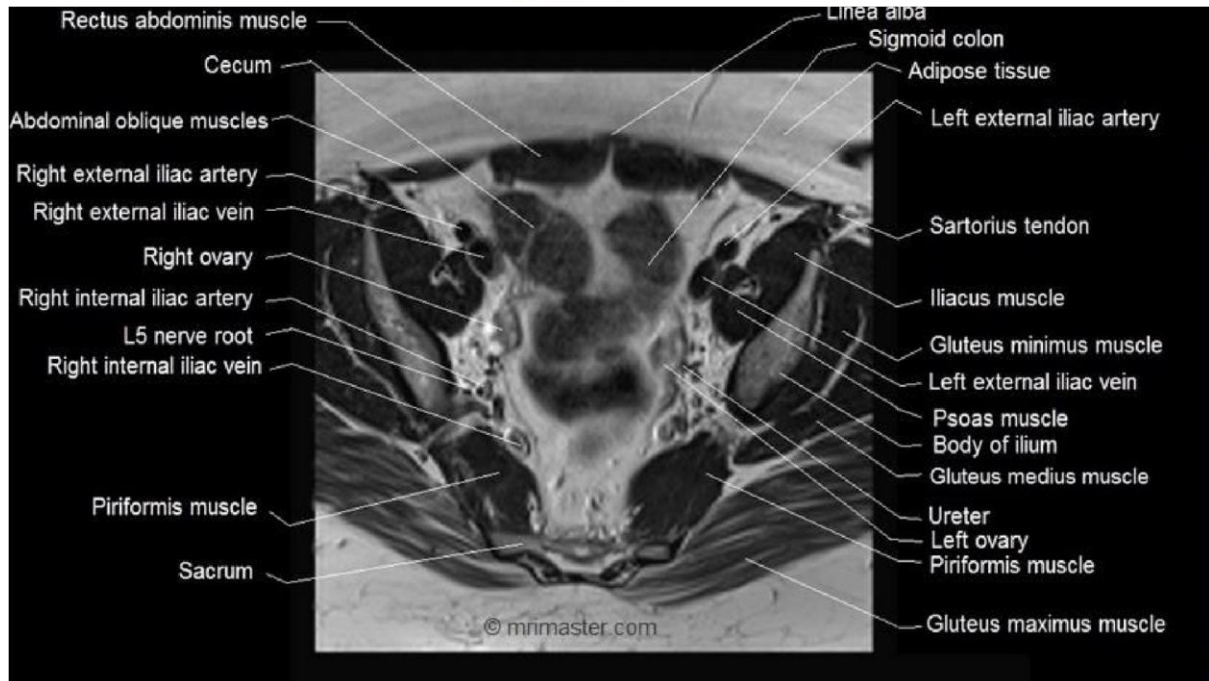
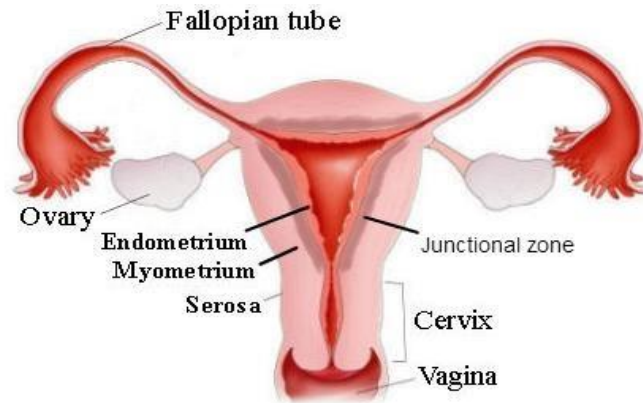
- † The level is above the bladder.
- † The sigmoid colon may be seen close to its junction with the rectum.
- † The sacrum lies posteriorly.



Cross sectional pelvic anatomy:

Lower sacral level (female)

- † The uterus is seen in close contact with the posterior surface of the bladder
- † The ovaries are either lateral to uterus or behind the ureters seen at posterior-lateral aspect of the bladder
- † **Perimetrium:** The outermost, protective layer.
- † **Myometrium:** The highly muscular middle layer. This is what expands during pregnancy and contracts to push your baby out.
- † **Endometrium:** The inner layer or lining of your uterus (uterine lining). This layer of uterus is shed during the menstrual cycle.



Cross sectional pelvicanatomy :

Lower sacral level (Male)

- † The bladder seen to have square shape (when it contains urine).
- † It extends anteriorly.
- † Posteriorly are the seminal vesicles.
- † The rectum is just behind the seminal vesicles.
- † The ureters seen at posterior-lateral aspect of the bladder.

Thank You!